

THE PRESENTATION, DIAGNOSIS AND TREATMENT OF MAST CELL ACTIVATION SYNDROME

Lawrence B Afrin, MD

Associate Professor, Division of Hematology, Oncology and Transplantation, University of Minnesota, Minneapolis, United States of America

Correspondence:

Lawrence B Afrin, email: afrinl@umn.edu

Keywords: Mast Cell; Mast Cell Activation Disease; Mast Cell Activation Syndrome; Chronic Inflammation; KIT Mutations

ABSTRACT

Only recently recognised, mast cell activation syndrome (MCAS) is a large, prevalent collection of illnesses resulting from mast cells (MCs) which are inappropriately activated but which, in contrast to the (collectively rare) forms of mastocytosis, are not significantly proliferating. Due to the diversity of direct and indirect, local and remote effects of the menagerie of mediators released by MCs, likely due to highly heterogeneous sets of mutations in MC regulatory elements, MCAS typically presents as chronic, persistent or recurrent, waxing/waning or slowly progressive, generally inflammatory multisystem polymorbidity. Initial manifestations often occur in childhood but are non-specific; in fact, virtually all of the syndrome's manifestations are non-specific, leading to decades of mysterious illness complicated by incorrect or superficial diagnoses often poorly responsive to empiric therapies. Diagnosis is further challenged in detecting specific biomarkers of MC activation other than serum tryptase levels, which usually are elevated in systemic mastocytosis but normal in MCAS. MCAS therapy aims to inhibit mediator production/release and block/ameliorate mediator action. Although patient-specific optimal therapy is not presently predictable, a methodical, persistent, trial-and-error approach usually finds helpful therapy. Lifespan with MCAS approximates normal, but quality of life can be significantly impaired without correct diagnosis and effective treatment.

INTRODUCTION: EMERGING APPRECIATION OF A MUCH LARGER SPECTRUM OF MAST CELL DISEASE

The year 2013 marked the sesquicentennial of the discovery of what today remains one of the most underappreciated developments in eukaryotic evolution, the mast cell (MC). German pathologist Friedrich von Recklinghausen first identified MCs (in frogs),¹ and in 1877 Paul Ehrlich first identified in human connective tissues these same cells, which he termed mastzellen, or well-nourished cells, due to their rich granular content.² A decade later, German dermatologist Paul Gerson Unna first associated MCs with human disease in the rare skin disease urticaria pigmentosa.³ Not until 1949, though, were MCs associated with internal disease in what we today call systemic mastocytosis (SM).⁴ Identification of MC products had begun in 1937 with the discovery that the metachromasia of MC granules is due to their heparin content,^{5,6} and in 1953 the MC's high histamine content was discovered.^{7,8} Ensuing decades saw development of the modern understanding of not only the hematopoietic origin of the normally widely, sparsely distributed MC but also its fundamental function,

namely, to produce and release a wide range of molecular signals, generally termed MC mediators and estimated to number from the dozens⁹ to perhaps more than 200,¹⁰ contributing to many processes including defence, growth, and healing. In 1987 tryptase was first defined as a highly sensitive and specific marker for MC activation,¹¹ but in the ensuing quarter century it has become apparent that serum tryptase levels reflect the body's total load of MCs more than the summative activation state of that load.^{12,13}

Insights into the molecular genetic roots of MC disease began emerging in 1993 with identification of the D816V activating mutation of the Kit transmembrane receptor tyrosine kinase, the extracellular portion of which is immunologically recognised as CD117.¹⁴ This mutation later was proved present in most adult SM.^{15,16} In 1998, it was shown that the MCs in many cases of SM, unlike any known normal cells, co-express the aberrant doublet CD117⁺CD25⁺ or CD117⁺CD2⁺, or sometimes even the aberrant triplet CD117⁺CD25⁺CD2⁺.¹⁷ In the last 20 years it has become apparent that MC accumulation in mastocytosis is due more to anti-apoptosis than frank proliferation.^{18,19,20,21,22,23,24,25,26,27}

Long after Unna's first association of MCs with a pathological state, MC disease (cutaneous or systemic) was still thought to be a disorder of MC proliferation ("mastocytosis") with most clinical consequences stemming from aberrant mediator release. In 1991, though, John Oates and Jack Roberts of Vanderbilt University hypothesised the existence of a spectrum of disorders of MC mediator release (i.e., MC activation) with little to no MC cytoproliferation.²⁸ Evidence for such MC activation disorders continued to accrue, and 2007 saw the first descriptions in the literature of "monoclonal MC activation syndrome" (MMCAS),^{29,30} shortly followed by the first formal proposal for diagnostic criteria.³¹ That same year, critical insight into the possible cause of the marked clinical heterogeneity of relatively non-proliferative MC activation syndrome (MCAS) was provided by German geneticist Gerhard Molderings and colleagues.³² Their finding of a large array of mutations in the mRNA for MC Kit (the MC's principal regulatory element) in a cohort of MCAS patients was repeated and extended in another study they reported in 2010 which included healthy controls in whom these mutations were largely absent.³³ (However, these findings await independent confirmation.) Simultaneously, multiple investigators reported that virtually all cases of mastocytosis, too, harbour multiple mutations (virtually always somatic) across many MC regulatory genes, epigenes, and microRNAs resulting in perturbances of a wide array of intracellular processes.^{34,35,36,37,38,39}

In late 2010, noted MC researchers Cem Akin, Peter Valent, and Dean Metcalfe proposed a fundamentally new conceptualisation that all MC disease first and foremost manifests aberrant MC activation, thus engendering a new top-level designation of "mast cell activation disease" (MCAD) to describe the full range of pathologic MC states.⁴⁰ The proliferative diseases of (rare) cutaneous mastocytosis and even rarer SM comprise one element of MCAD, while various forms of the relatively non-proliferative MCAS (suggested by preliminary data as virtually epidemic^{41,42} but only rarely demonstrable by presently available testing as MMCAS) comprise other elements of MCAD. According to this proposal, MCAS could be diagnosed if the patient repeatedly demonstrated symptoms consistent with aberrant MC mediator release, laboratory evidence of such release, absence of any other disease better fitting the entire clinical picture, and at least partial response to therapy targeted at MCs or MC mediators. However, as the mutational heterogeneity of MCAS effects substantial clinical and therapeutic heterogeneity, some felt a diagnostic criterion for therapeutic response was

impractical.⁹ A year later Valent et al. published an updated proposal for diagnostic criteria for MCAS in which the diagnostic requirement for therapeutic response was relaxed (i.e., desirable but not necessary) and laboratory diagnostic criteria were streamlined to focus solely on tryptase.⁴³ However, problematic aspects of this proposal, too, have been identified.⁴⁴ Meanwhile, in 2011 Molderings et al. published an alternative diagnostic proposal which is structured akin to the World Health Organization (WHO) 2008 diagnostic criteria for SM,⁴⁶ makes diagnostic use of specific MC mediators beyond just tryptase, and does not require demonstration of therapeutic response.

Although it seems likely that any given clinical presentation of MCAD results from a specific set of mutations driving a specific pattern of both aberrant constitutive activation and aberrant reactivity in MCs (due to mutations in the MCs themselves as well as effects on normal and abnormal MCs and other cell lineages likely harbouring much the same mutations), at present the range of mutations in MC regulatory elements for which commercial testing is widely available is still very limited (essentially only probing for KIT-D816V). Thus, the question is raised as to whether "primary idiopathic MCAS"⁴⁷ might be more accurately termed "MCAS of undetermined clonality". When more readily available, whole KIT (or whole genome/exome) sequencing of isolated MCs will help settle this matter.

Thus, after roughly 150 years of medical orthodoxy that MC disease is principally only a rare, cytoproliferative process called mastocytosis, in merely the last seven years it has become readily apparent that mastocytosis is but the tip of the proverbial iceberg of MC disease (Figure 1), with the far more common but relatively non-proliferative MCAS comprising the large bulk of the iceberg, largely unseen or unrecognized for many reasons to be reviewed below.

Given that the principal distinctions between MCAS and mastocytosis are pathologic findings (e.g., significantly elevated serum tryptase and MC proliferation in mastocytosis) which appear to be clinically inconsequential except in the particularly rare, aggressive forms of mastocytosis, comments below about MCAS largely apply to mastocytosis as well; exceptions are highlighted.

PRESENTATION OF MAST CELL ACTIVATION SYNDROME

As seen now in most such patients investigated by whole KIT mRNA sequencing,^{32,33} the mutational roots of MCAS are markedly heterogeneous and thus lead to expectation

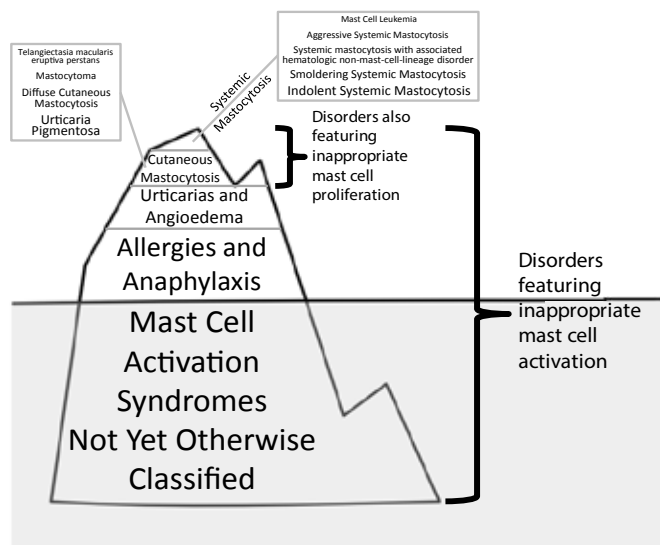


Figure 1. An iceberg-type metaphoric conception of the spectrum of disorders of mast cell (MC) activation listed in Reference 40, with typically vividly presenting entities arrayed above a “waterline” of relatively easy clinical recognisability in order of estimated prevalence.^{41,64,65,66,67,68,69} The most recently recognised entity, MC activation syndrome (MCAS), with recent preliminary prevalence estimates of 14-17%,^{41,42} may be “hidden below the waterline,” or more difficult to clinically recognise, due to heterogeneity of presentation, fewer visually distinctive signs, and other factors. The various forms of mastocytosis are mutationally rooted primary MC diseases,^{34,70} as are rare variants of MCAS which can be proven monoclonal³¹ (though clinical laboratory testing for such at present is largely constrained to (1) probing by polymerase chain reaction for the constitutively activating KIT-D816V mutation, and (2) testing by flow cytometry for MCs bearing pathognomonically aberrant CD117⁺CD25⁺ or CD117⁺CD2⁺ signatures which, when present, often comprise very small portions (< 1%) of the tested cell population). Other classic MC activation disorders have long been thought to be secondary/reactive MC diseases, though more extensive mutational analyses have suggested recently that most MCAS cases, like mastocytosis, are also mutationally rooted.^{32,33}

of heterogeneity in clinical presentation. It also seems likely that evolving genomic disruption may herald clinical progression.

Although symptoms can initially appear at any age, most commonly MCAS initially presents in adolescence or childhood, sometimes even infancy, though the non-specific nature of almost every symptom of the disease foils clinical recognition until years or decades later, if ever.⁴⁵ Symptoms often, but not always, are of an “inflammatory”

nature and can arise acutely, subacutely, or chronically (i.e., developmentally). Symptoms often persist, waxing and waning to varying degrees at often unpredictable time points, and sometimes can wholly remit and then (again usually unpredictably) episodically relapse. Especially given their common absence of histologically detectable MC cytoproliferation, MCAS patients are generally regarded as inexplicably chronically multisystemically ill, perhaps recognised as likely having an underlying inflammatory issue of some sort but without fitting the pattern of any well-known such syndrome. Disability is common and can be severe.

“Routine” diagnostic testing often yields normal or “borderline” results, or mild to moderate abnormalities which often prove ephemeral. Though their presenting symptoms in any given system are most commonly subtle to moderate, occasionally MCAS patients will present severe, even life-threatening abnormalities (e.g., end-stage renal failure^{48,49,50} or refractory diarrhoea⁵¹), with “exhaustive” diagnostic testing failing to reveal a specific aetiology. Also reflecting its heterogeneity, MCAS can present with polar opposite abnormalities in different patients (e.g., gastrointestinal dysmotility principally manifesting as diarrhoea in one patient vs. constipation in another patient, or dyserythropoiesis principally manifesting as erythrocytosis in one patient⁵² vs. pure red cell aplasia in another patient⁵³). MCAS patients sometimes even “swing” between the ends of the scale for any given parameter; for example, alternation between diarrhoea and constipation is common in MCAS. Acute emergence of “flares,” “spells,” or “episodes” of assorted symptoms is common, often leading to urgent evaluations which, though necessary to exclude other illnesses, usually are frustratingly unrevealing and often lead to suspicions of psychosomatism.

MCAS patients often respond incompletely (or intolerantly) to therapies which are targeted at their superficial ailments and which are effective and well tolerated in most other patients. Although no formal epidemiologic studies have yet been reported, MCAS appears in general to course similarly to indolent SM (ISM), in which survival appears equivalent to that of the general population, though often with reduced quality of life.

Some MCAS patients who are not yet so recognised also have definitively diagnosed inborn or acquired comorbid ailments (e.g., sickle cell anaemia or obesity) which come to be blamed by many of their physicians for most or all of their symptoms even though it may be difficult to biologically attribute some of their symptoms to such ailments.

The MCAS patient not uncommonly can identify a specific point at which his/her general health took a distinct turn for the worse. Such points commonly soon follow acute events of significant psychological or physical stress (e.g., death of a family member, or vehicular trauma) or of significant new antigenic exposure (e.g., food or travel). If they have recognised the temporal association between trigger and illness, such patients not uncommonly are convinced that the trigger was the cause of the illness. However, careful history-taking virtually always reveals some symptoms of MCAS to have been present long before “the turning point.”

Once chronic clinical illness from MCAS has developed, it may remain stable for years, but stepwise escalations in baseline symptomatology are common and, as with the initial clinical emergence of the illness, often follow acute physical or psychological stressors (including puberty, especially menarche, leading to menstrually cyclic flares). Adolescents with MCAS sometimes experience spontaneous improvement in their late teens as pubertal processes abate, but the illness often re-emerges within the next decade or so.

Obtaining a complete medical history is paramount in establishing grounds for clinical suspicion of MCAS. History-taking must include a complete review of systems (ROS), as many MCAS patients have been ill for so long that they come to accept various aspects of their illness as a baseline “healthy” state for them. In fact, after extensive evaluations over many years have failed to identify a diagnosis, let alone effective therapy, patients sometimes omit certain aspects of their illness when reiterating history to yet another physician, underscoring the importance of the ROS.

A systematic listing of MCAS symptoms is presented in Table I. More detail is available in a recent comprehensive review.⁵⁴

DIAGNOSIS OF MAST CELL ACTIVATION SYNDROME

MCAS seems engineered to confound diagnosticians. Its likely great menagerie of underlying activating mutations, combined with the MC’s normal function of producing and releasing a cornucopia of potent mediators (each with multiple direct and indirect, local and remote effects)¹⁰ ensures tremendous diversity of clinical presentation. The typical MCAS patient presents with many symptoms and findings, many having been endured for many years, and with different symptoms confoundingly more prominent

at different times. Although the motif of MCAS’s clinical presentation is chronic multisystem polymorbidity of mostly an inflammatory nature, many elements of the presentation are not clearly “inflammatory” (e.g., fatigue, osteopenia, paraesthesias). Moreover, many other elements, while discovered relatively recently to truly be inflammatory in nature, are not yet appreciated in that regard by most physicians (e.g., atherosclerotic vascular disease, obesity, psychoses).

Thus, the repetition in presentation that helps diagnosticians recognise most diseases is muted in MCAS. Even physicians familiar with MCAS may diagnose such in many patients before finding one whose presentation closely resembles another’s. Other practical factors, too – such as the modern trend in physician practice toward subspecialisation, and health care financing systems which disincentivise spending the extended time needed to recognise multisystem problems – further impede diagnosis of this prototypical multisystem disease.

Nevertheless, the diagnostician can be aided in suspecting MCAS by remembering a few simple tips:

- 1) MCAS usually presents as chronic multisystem polymorbidity, generally of an inflammatory theme and with assorted elements waxing and waning over time, sometimes in synchronisation with one another but more often cycling with different periods and amplitudes.
- 2) When there are symptoms and findings not readily attributable to the patient’s established diagnoses, alternative diagnoses must be entertained to account for these “leftover” elements, and it becomes more likely, as per Occam’s Razor, that the same diagnosis that accounts for the leftover elements also is at the root of the established non-congenital diagnoses.
- 3) The range of MC mediators and their effects is so great that “unusual” presentations actually become *de rigueur*. That is to say, although any given unusual presentation remains unusual, the full set of unusual presentations constitutes a sizable fraction of the total set of presentations. Thus, when the clinician recognises an “unusual,” “odd”, “weird”, “bizarre,” or “strange” element in the patient’s presentation – e.g., “allergies” to typically innocuous medications, migratory rather than dependent oedema, frequent presyncope accompanying hematologic malignancy

Table I: Symptoms and findings in mast cell activation disease (MCAD). Most are chronic but may be acutely episodic or wax and wane. Severity is variable across patients and may vary in a given patient over time.

Constitutional	Fatigue, malaise, asthenia, “chronic fatigue syndrome,” subjective and/or objective hyperthermia and/or hypothermia, “sense of feeling cold much of the time,” sweats/diaphoresis (not always nocturnal), flushing, plethora or pallor, increased or decreased appetite, early satiety, weight gain or loss, pruritus, chemical and/or physical environmental sensitivities (often odd)
Dermatologic/ Integument	Rashes and lesions of many sorts (classic urticaria pigmentosa, “freckles,” telangiectatic/angiomatic lesions, xerosis, warts, tags, folliculitis, ulcers, dyshydrotic eczema, diffusely migratory but sometimes focally persistent patchy macular erythema), pruritus (often diffusely migratory, sometimes aquagenic), flushing, angioedema, striae, dermatographism, hair thinning and alopecia, onychodystrophy (brittle nails, longitudinal ridges), poor healing
Ophthalmologic	Irritated eyes, increased or decreased lacrimation, suffusion, conjunctivitis, episodic difficulty focusing, lid tremor/tic (blepharospasm), solar sensitivity, infectious or sterile inflammation
Otologic/Osmic	Infectious or sterile otitis externa and/or media, hearing loss or hyperacusis, tinnitus, otosclerosis, dysosmia, coryza, congestion
Oral/oropharyngeal	Pain or irritation (sometimes “burning”), leukoplakia, fibrosis, lichen planus, ulcers, sores, angioedema, dental decay, dysgeusia, throat tickle/discomfort/irritation/pain, post-nasal drip
Lymphatic	Adenopathy, usually sub-pathologic and often waxing/waning in size, sometimes asymptomatic but not uncommonly tender, sometimes focal, sometimes migratory, pathology usually shows reactive lymphocytosis or sometimes an atypical non-specific lymphoproliferative disorder; left upper quadrant discomfort (likely from release of mediators from splenic MCs with or without detectable splenomegaly)
Pulmonary	Rhinitis, sinusitis, pharyngitis, laryngitis, bronchitis, pneumonitis (often confused with infectious pneumonia), cough, dyspnea (often low-grade, inconstant, “I just can’t catch a deep breath” despite normal pulmonary function tests), wheezing, obstructive sleep apnea, pulmonary hypertension
Cardiovascular	Presyncope (lightheadedness, weakness, dizziness, vertigo) and/or syncope (patients may have been diagnosed with postural orthostatic tachycardia syndrome or neurocardiogenic syncope), hypertension and/or hypotension, palpitations, dysrhythmias, chest discomfort or pain (usually non-anginal in character), coronary and peripheral arterial atherosclerosis/spasm/infarction, idiopathic acute or chronic heart failure (e.g., takotsubo), aneurysms, hemorrhoids, varicosities, aberrant angiogenesis (hemangiomas, arteriovenous malformations, telangiectasias), migratory edema (often non-dependent and with normal cardiac and renal function)
Gastrointestinal	Aerophagia, angioedema in any segment of the luminal tract, dysphagia (often proximal, possibly due to pharyngeal angioedema), bloating/gas, pain/inflammation (often migratory) in one or more segments of the luminal tract (from esophagitis to proctitis) and/or one or more solid organs (e.g., hepatitis, pancreatitis), queasiness, nausea, vomiting (sometimes “cyclical”), diarrhoea and/or constipation (often alternating), malabsorption (more often selective micronutrient malabsorption than general protein-calorie malabsorption), ascites either from portal hypertension and/or peritoneal serositis; gastroesophageal reflux disease (often “treatment-refractory”) and inflammatory/irritable bowel syndrome are common pre-existing diagnoses

Table I: Continued

Genitourinary	Inflammation (often migratory) in one or more segments of the luminal tracts (ureteritis, cystitis, urethritis, vaginitis, vestibulitis) and/or one or more solid organs (e.g., nephritis, prostatitis), chronic kidney disease, endometriosis, ovarian cysts, chronic low back pain or flank pain or abdominal pain, hydro-nephrosis (likely from stone disease and/or ureteral angioedema), infertility, erectile dysfunction, decreased libido; in the appropriate setting of multisystem morbidity, miscarriages should prompt consideration of antiphospholipid antibody syndrome potentially due to MCAD
Musculoskeletal	Clinical myositis, often diffusely migratory (fibromyalgia is a common pre-existing diagnosis), subclinical myositis (i.e., asymptomatic elevated creatine kinase and/or aldolase not otherwise explained), arthritis (typically migratory and not fitting any defined rheumatologic entity), joint laxity/hypermobility (patients may have been diagnosed with Ehlers-Danlos Syndrome Type III), osteoporosis/osteopenia, osteosclerosis, sometimes mixed osteoporosis/osteopenia/osteosclerosis; MCAD-driven musculoskeletal pain not uncommonly is poorly responsive to non-steroidal anti-inflammatory drugs and narcotics
Neurologic	Headache (esp. migraine), presyncope and/or syncope, peripheral (usually distal and migratory) sensory and/or motor neuropathies including paresthesias, tics, tremors (typically resting), chronic inflammatory demyelinating polyneuropathy, seizure disorders (can be “treatment-refractory”), pseudoseizures, dysautonomia
Psychiatric	Mood disturbances (e.g., anger, depression) and lability, bipolar affective disorder, attention deficit-hyperactivity disorder, post-traumatic stress disorder, anxiety and panic, psychoses, memory difficulties, word-finding difficulties, other cognitive dysfunction, wide variety of sleep disruptions
Endocrinologic/ Metabolic	Abnormal electrolytes (including magnesium) and liver function tests, delayed puberty, dysmenorrhea, endometriosis, osteosclerosis and/or osteoporosis, hypothyroidism, hyperthyroidism, dyslipidemia, hyperferritinemia, selective vitamin and/or other micronutrient deficiencies, weight change, possibly diabetes mellitus
Hematologic/ Coagulopathic	Polycythemia or anemia (may be macrocytic, normocytic, or microcytic), leukocytosis or leukopenia, chronic (usually mild) monocytosis or eosinophilia or basophilia, thrombocytosis or thrombocytopenia, arterial and/or venous thromboembolic disease, “easy” bruising/bleeding; in MCAS (as opposed to systemic mastocytosis) the marrow usually does not show increased (or even flow-cytometrically aberrant) MCs and marrow histology is often read as normal or as unspecified myelodysplastic/myeloproliferative syndrome; standard cytogenetic studies are almost always normal or show culture failure
Immunologic	Type I, II, III, and IV hypersensitivity reactions, increased risk for malignancy, autoimmunity (again potentially any autoantigen, often without the expected associated clinical syndrome and with inexplicably significantly fluctuating autoantibody titers), impaired healing, increased susceptibility to infection, elevated or decreased levels of one or more isotypes of immunoglobulin; modest monoclonal gammopathy of undetermined significance not uncommon

- his “MCAS radar” should go on alert. The presence of an unusual element in the presentation by no means establishes a diagnosis of MCAS, but it sometimes can be the first spark toward lighting a fire of recognition.

its novelty and its heterogeneity. Once MCAS is suspected, though, how should the diagnostic evaluation proceed?

Particularly given that MCAS and its relationship to MCAD have come to be recognised only recently, it is not surprising that there is not yet definitive global consensus regarding

Thus, the largest impediments to diagnosing MCAS may be

diagnostic criteria for MCAS or the diagnostic approach to the full realm of MCAD. Figure 2 illustrates the established diagnostic criteria for SM and the two current proposals for diagnostic criteria for MCAS.

Given the new understanding that serum tryptase levels reflect body MC load more so than MC activation state, one diagnostic approach detailed recently (Figure 3⁴⁴) begins with using the tryptase level (typically significantly elevated in SM but elevated little to none in MCAS^{33,45}) to determine whether evaluation should be directed more toward SM (focusing more on searching tissues, such as marrow, for abnormally aggregated MCs) or MCAS (focusing more on searching for elevated levels of MC mediators). Many MC mediators are thermolabile and have short half-lives, requiring diligent attention to specimen cooling, and non-steroidal anti-inflammatory drugs and proton pump inhibitors can be confounding factors, too; these and other nuances of diagnostic testing for MCAS are discussed elsewhere.⁴⁴

Because MCAS is a relatively non-proliferative MC disease, none of the recent proposals for diagnostic criteria for MCAS requires histologic detection of increased numbers, or aberrant immunophenotypes or genotypes, of MCs. In fact, neither the Akin et al. 2010 criteria⁴⁰ nor the Valent et al. 2012 criteria⁴³ make any mention of histologic detection. However, histologic detection of quantitative or qualitative MC aberrancy can be used, per the Molderings et al. 2011 criteria,⁴⁵ to support the diagnosis. As MCs typically reside at the environmental interfaces,^{55,56} histologic evidence of disease sometimes can be found at such locales.

Because MCs spend little of their early formative time in the marrow^{55,57,58} and proliferate little in MCAS, MCAS is rarely detectable - histologically, immunophenotypically, or genotypically, using presently commercially available techniques - in marrow.⁴⁵ Therefore, in contrast to evaluations for SM (which is suspected when serum tryptase consistently exceeds 20 ng/ml, approximately twice the upper limit of normal) marrow examinations presently do not seem useful enough to warrant being mandatory in evaluations for MCAS. It is possible that a small portion of SM cases (per the WHO 2008 criteria⁴⁶) may be missed by not examining marrow in MCAS patients with serum tryptase below 20 ng/ml, but the largest portion of SM patients fall into the category of ISM,^{59,60} whose prognosis and treatment presently are not known to be significantly different than seen and applied in MCAS. Furthermore, the more morbid (and usually more proliferative) forms of SM warranting more aggressive (often cytotoxic) therapies

present normal tryptase levels even more rarely than ISM and also typically present aggressive clinical features, quickly engendering biopsy and histologic identification of the true diagnosis. Thus, although it is important to distinguish aggressive forms of SM from MCAS, the likelihood of confusing these entities is low.

Laboratory techniques for detecting MCAS (and mastocytosis) likely will advance rapidly. The greater challenge will remain sparking initial suspicion of the diagnosis. In the future, computer-aided diagnostic tools built into electronic clinical information systems may help clinicians recognise morbidity patterns consistent with MCAS.

TREATMENT OF MAST CELL ACTIVATION SYNDROME

Symptoms and other clinical consequences (e.g., blood count abnormalities) in MCAS and ISM result primarily from aberrant mediator release. Also, because of potential circulation of released mediators and interaction of released mediators with other systems, dysfunctional MCs may or may not be located near the clinically affected site. Thus, therapies for MCAS and ISM (as summarised in Table II and discussed in detail elsewhere in the literature, e.g., Reference 54) primarily aim to (1) reduce MC production and release of mediators, (2) interfere with released mediators, and (3) counter unavoidable effects of released mediators. (Comments below about treatment for MCAS also apply to ISM.) MCAS's heterogeneity in mutational patterns, mediator expression patterns, and clinical presentation patterns virtually ensures heterogeneity of therapeutic response. Both clinician and patient must be patient, persistent, and methodical in stepping through available therapies until the patient achieves the palliative goal of identifying a regimen that helps him/her feel significantly better than the pre-treatment baseline the majority of the time. The substantially morbid cytotoxic and cellular therapies typically reserved for more aggressive forms of mastocytosis appear to have no role at present in the management of MCAS.

Avoidance of triggers, desensitisation therapy (when specific unavoidable environmental triggers can be identified) and prophylactic therapies (e.g., bisphosphonate therapy for osteoporosis) help limit morbidity from MCAS. Patients susceptible to anaphylaxis should be prescribed epinephrine auto-injectors and instructed in their proper use. In spite of their fatigue, malaise, and physical and antigenic sensitivities, MCAS patients should be encouraged to regularly exercise, but only to the limit of tolerance since

exertion clearly triggers flares in some patients. Dietary guidance is difficult to provide, as dietary sensitivities vary substantially amongst MCAS patients. Perioperative management of mastocytosis has been described in detail,⁶¹ and it seems prudent to approach MCAS similarly.

In view of the innate complexity of the disease and its potential for reacting adversely to new exposures, it is important to try to make only one change in the MCAS patient's regimen at any given time.⁶² Both active and inactive medication ingredients can offend MCAS patients. Therefore, sometimes a change in a medication's formulation can provoke, or quell, a flare. Sometimes

custom-compounded formulations are required to avoid provocative inactive agents in commercial medication formulations.

Given the rarity of mastocytosis, together with how recently MCAS has come to be recognised, there are no large controlled studies of any intervention for mastocytosis or MCAS. The absence of such data, the underlying mutational heterogeneity of MCAS, and the poor correlation between any given symptom (which can arise via multiple mechanisms) and its effective therapies means that at present the clinician largely cannot foretell which interventions are most likely to benefit the individual MCAS

Table II: Treatments used in mast cell activation disease

Mechanism of action	Therapies / Therapeutic Classes
Anti-mediator (inhibition of MC mediator production or action)	Histamine H ₁ receptor antagonists Histamine H ₂ receptor antagonists Non-steroidal anti-inflammatory drugs Benzodiazepines Corticosteroids Leukotriene receptor antagonists Proton pump inhibitors Tricyclic antidepressants (antihistaminic) Phenothiazines (antihistaminic) Hydroxyurea Bisphosphonates, vitamin D, calcium 5-hydroxytryptamine ₃ receptor antagonists Ivabradine Icatibant Alpha lipoic acid Ascorbic acid N-acetylcysteine Amphetamines Hypolipidemics
Mast cell stabilizers	Cromolyn Quercetin Ketotifen Pentosan Tyrosine kinase inhibitors (e.g., imatinib) Alpha interferon
Cytostatic/cytotoxic agents	Cladribine Pentostatin Fludarabine Paclitaxel Alkylators (e.g., cyclophosphamide) Hydroxyurea
Immunomodulation	Allergy desensitization therapy Allogeneic stem cell transplantation

WHO 2008 Diagnostic Criteria for Systemic Mastocytosis⁴⁶

Major Criterion:

1. Multifocal, dense aggregates of MCs (15 or more) in sections of bone marrow or other extracutaneous tissues and confirmed by tryptase immunohistochemistry or other special stains.

Minor Criteria:

1. Atypical or spindled appearance of at least 25% of the MCs in the diagnostic biopsy;
2. Expression of CD2 and/or CD25 by MCs in marrow, blood, or extracutaneous organs;
3. KIT codon 816 mutation in marrow, blood, or extracutaneous organs;
4. Persistent elevation of serum total tryptase > 20 ng/ml.

Diagnosis of SM made by either (1) major criterion + any one or more minor criteria, or (2) any three minor criteria.

Proposed Diagnostic Criteria for Mast Cell Activation Syndrome

Valent et al. Criteria⁴³

1. Chronic/recurrent symptoms (flushing, pruritus, urticaria, angioedema, nasal congestion or pruritus, wheezing, throat swelling, headache, hypotension, and/or diarrhea) consistent with aberrant MC mediator release;
2. Absence of any other known disorder that can better account for these symptoms;
3. Increase in serum total tryptase of [20% above baseline, plus another 2 ng/ml] during, or within 4 hours after, a symptomatic period;
4. Response of symptoms to histamine H₁ and/or H₂ receptor antagonists or other "MC-targeting" agents such as cromolyn.

Molderings et al. Criteria⁴⁵

Major Criteria:

1. Multifocal MC aggregates as per WHO major criterion for SM;
2. Clinical history consistent with chronic/recurrent aberrant MC mediator release (symptoms per Table 3 in Reference 45).

Minor Criteria:

1. Abnormal MC morphology as per WHO SM minor criterion #1;
2. CD2 and/or CD25 expression as per WHO SM minor criterion #2;
3. Detection of known constitutively activating mutations in MCs in blood, marrow, or extracutaneous organs;
4. Elevation in serum tryptase or chromogranin A, plasma heparin or histamine, urinary N-methylhistamine, and/or other MC-specific mediators such as (but not limited to) relevant leuko-trienes (B4, C4, D4, E4) or PGD₂ or its metabolite 11-β-PGF_{2α}.

Diagnosis of MCAS made by either (1) both major criteria, or (2) the second major criterion plus any one of the minor criteria, or (3) any three minor criteria.

Figure 2. Diagnostic criteria for systemic mastocytosis (SM) and mast cell activation syndrome (MCAS). MC: mast cell; PG: prostaglandin; WHO: World Health Organization.

patient. For more aggressive forms of SM, enrolment in a clinical trial of novel therapy is the best option. Some

novel therapies (e.g., masatinib) have completed successful trials in aggressive SM and are now being explored in

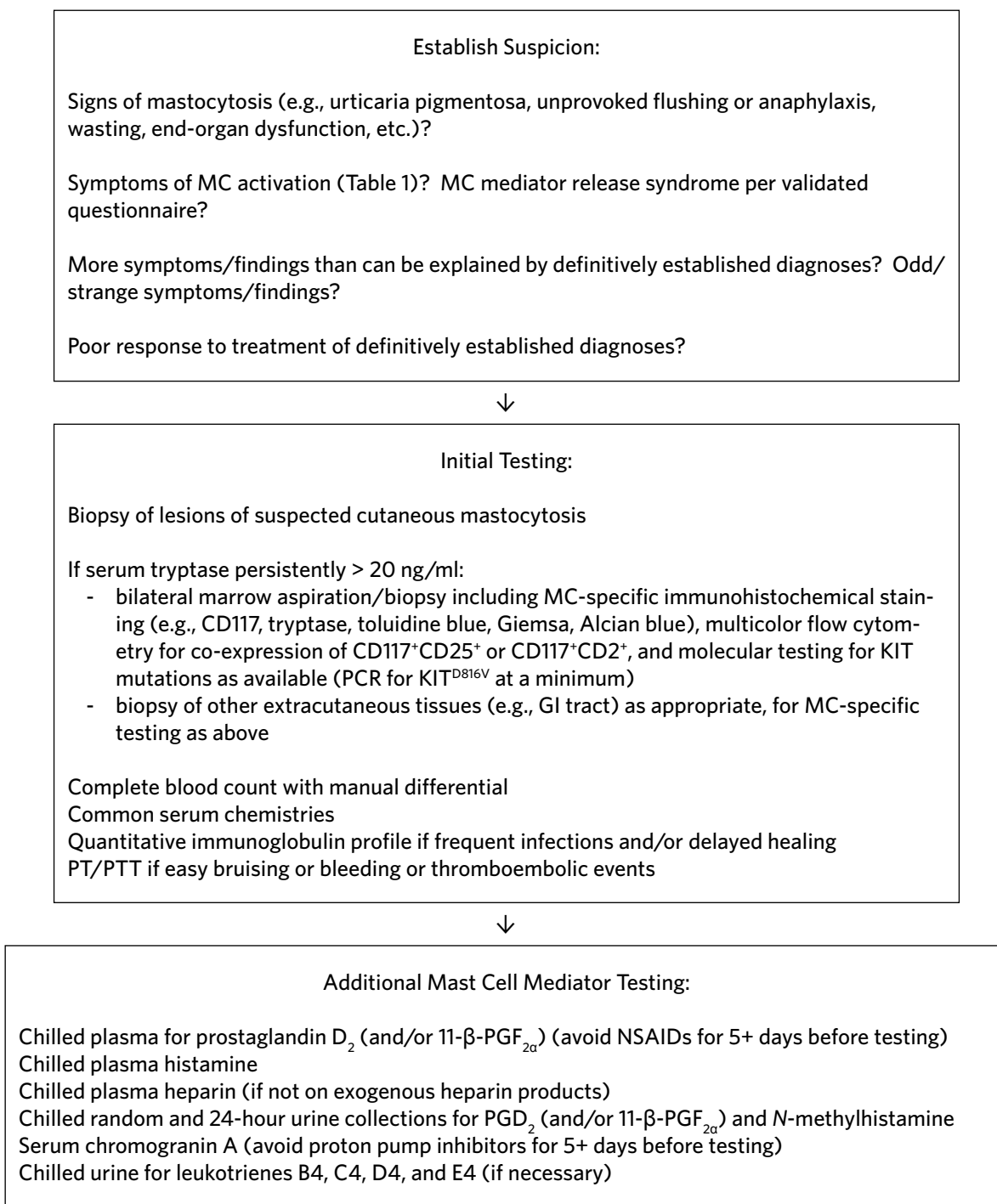


Figure 3. A suggested diagnostic approach to mast cell (MC) activation disease including mastocytosis and MCAS.

ISM. When investigational therapy is not an option for the patient with aggressive mastocytosis, the ad hoc cytotoxic therapies commonly tried (e.g., cladribine, interferon) usually yield modest response rates and durations at the cost of significant toxicities, such approaches have been reviewed elsewhere.⁶⁰ There have been no controlled

trials of any therapy yet in MCAS. For ad hoc treatment of MCAS, an economics-based strategy for determining the order in which to try assorted therapies seems reasonable, starting with inexpensive therapies and escalating in cost as necessary. Some patients achieve sufficient control at little expense, but many require expensive regimens that can be

challenging to initiate or sustain.

Secondary issues in MCAS (e.g., inflammation, infection, autoimmunity, malignancy, coagulopathy, osteopathy, etc.) not uncommonly come to clinical attention first, but regardless of whether such issues present prior or subsequent to diagnosis of MC disease, they warrant standard therapy and may fare better when MCAS is recognised and concomitantly specifically addressed, such as can be seen in the setting of SM with an associated hematologic non-mast-cell-lineage disorder (e.g., leukaemia or lymphoma).⁶³

CONCLUSIONS

MCAS is a recently recognised, prevalent collection of chronic, generally inflammatory multisystem illnesses likely born of marked mutational heterogeneity in MC regulatory elements, causing heterogeneous patterns of constitutive MC activation, leading to marked clinical heterogeneity which can be diagnostically and therapeutically confounding. In contrast to the forms of mastocytosis, which are much rarer than MCAS, the mutational patterns in MCAS do not drive significant MC proliferation. Thus, classic pathologic hallmarks used in diagnosing mastocytosis (e.g., significantly elevated serum tryptase (more marking MC load than activation), the KIT-D816V mutation, CD117⁺CD25⁺ or CD117⁺CD2⁺ expression, and abnormal MC morphology or aggregation) are rare in MCAS, and laboratory evaluation when MCAS is suspected instead focuses on markers of MC activation once mastocytosis and other diseases potentially providing unifying explanations for the symptoms and findings in the case have been ruled out. While their lifespans typically are normal, MCAS patients often suffer diminished quality of life until the disease is diagnosed and effectively treated. With patience, persistence, and a methodical approach, most MCAS patients are able to eventually identify a therapeutic regimen which helps them feel significantly better the majority of the time. Although such efforts may require many medication trials and much time, many MCAS patients have been ill for far longer and, simply by having finally identified a diagnosis and prognosis, are bolstered to endure the “trial-and-error” needed to identify effective therapy. Much research in MC disease remains to be done, but educational needs are equally great.

DECLARATION OF CONFLICT OF INTEREST

The author declares no conflict of interest.

REFERENCES

1. Von Recklinghausen F. Ueber eiter- und bindegewebskörperchen. *Virchows Arch* 1863;28:157-197.
2. Ehrlich P. Beiträge zur Kenntnis der Anilinfärbungen und ihrer Verwendung in der Mikroskopischen Technik. *Arch Mikrosk Anat* 1877;13:263-277.

3. Unna P. Beiträge zur Anatomie und Pathogenese der urticaria simplex und pigmentosa. *Monatsschrift der praktischen Dermatologie* 1887;6:9-18.
4. Ellis JM. Urticaria pigmentosa: report of a case with autopsy. *Arch Pathol* 1949;48(5):426-435.
5. Holmgren H, Wilander O. Beiträge zur Kenntnis der Chemie and Funktion der Ehrlichschen ästzellen. *Z Mikroskop Anat Forsch* 1937;42:242-278.
6. Jorpes E, Holmgren H, Wilander O. Über das Vorkommen von Heparin in den Gefäßwänden und in den Augen. *Z Mikroskop Anat Forsch* 1937;42:279-300.
7. Riley JF. Histamine in tissue mast cells. *Science* 1953;118:332-333.
8. Riley JF, West GB. The presence of histamine in tissue mast cells. *J Physiol (Lond)* 1953;120:528-537.
9. Molderings GJ, Homann J, Raithe M, Frieling T. Toward a global classification of mast cell activation diseases. *J Allergy Clin Immunol* 2011 May;127(5):1311.
10. Ibelgaufts H. “Mast Cells” in COPE: Cytokines and Cells Online Pathfinder Encyclopaedia, 2012. Available at <http://www.copewithcytokines.de/cope.cgi?key=mast%20cells> (accessed March 28, 2014).
11. Schwartz LB, Metcalfe DD, Miller JS, Earl H, Sullivan T. Tryptase levels as an indicator of mast-cell activation in systemic anaphylaxis and mastocytosis. *N Engl J Med* 1987;316:1622-1626.
12. Schwartz LB, Sakai K, Bradford TR, Ren SL, Zweiman B, Worobec AS, et al. The α form of human tryptase is the predominant type present in blood at baseline in normal subjects and is elevated in those with systemic mastocytosis. *J Clin Invest* 1995;96:2702-10.
13. Borer-Reinhold M, Haeberli G, Bitzenhofer M, Jandus P, Hausmann O, Fricker M, Helbling A, Müller U. An increase in serum tryptase even below 11.4 ng/mL may indicate a mast cell-mediated hypersensitivity reaction: a prospective study in Hymenoptera venom allergic patients. *Clin Exper Allergy* 2011 Dec;41(12):1777-1783.
14. Furitsu T, Tsujimura T, Tono T, Ikeda H, Kitayama H, Koshimizu U, Sugahara H, Butterfield JH, Ashman LK, Kanayama Y, Matsuzawa Y, Kitamura Y, Kanakura Y. Identification of mutations in the coding sequence of the proto-oncogene *c-kit* in a human mast cell leukemia cell line causing ligand-independent activation of *c-kit* product. *J Clin Invest* 1993;92:1736-1744.
15. Nagata H, Worobec AS, Oh CK, Chowdhury BA, Tannenbaum S, Suzuki Y, Metcalfe DD. Identification of a point mutation in the catalytic domain of the protooncogene *c-kit* in peripheral blood mononuclear cells of patients who have mastocytosis with an associated hematologic disorder. *Proc Natl Acad Sci USA* 1995 Nov;92:10560-10564.
16. Garcia-Montero AC, Jara-Acevedo M, Teodosio C, Sanchez ML, Nunez R, Prados A, Aldanondo I, Sanchez L, Dominguez M, Botana LM, Sanchez-Jimenez F, Sotlar K, Almeida J, Escribano L, Orfao A. *KIT* mutation in mast cells and other bone marrow hematopoietic cell lineages in systemic mast cell disorders: a prospective study of the Spanish Network on Mastocytosis (REMA) in a series of 113 patients. *Blood* 2006 Oct 1;108(7):2366-2372.
17. Escribano L, Orfao A, Diaz-Agustin B, Villarrubia J, Cerveró C, López A, Marcos MAG, Bellas C, Fernández-Cañadas S, Cuevas M, Sánchez A, Velasco J, Navarro JL, San Miguel JF. Indolent systemic mast cell disease in adults: immunophenotypic characterization of bone marrow mast cells and its diagnostic implications. *Blood* 1998 Apr 15;91(8):2731-2736.
18. Iemura A, Tsai M, Ando A, Wershil BK, Galli SJ. The *c-kit* ligand, stem cell factor, promotes mast cell survival by suppressing apoptosis. *Am J Pathol* 1994 Feb;144(2):321-328.
19. Metcalfe DD, Mekori JA, Rotten M. Mast cell ontogeny and apoptosis. *Exp Dermatol* 1995 Aug;4(4):227-230.
20. Ekoff M, Lyberg K, Krajewska M, Arvidsson M, Rak S, Reed JC, Harvima I, Nilsson G. Anti-apoptotic Bfl-1 is the major effector in activation-induced human mast cell survival. *PLoS ONE* 2012;7(6):e39117.
21. Karlberg M, Xiang Z, Nilsson G. Fc γ RI-mediated activation of human mast cells promotes survival and induction of the pro-survival gene Bfl-1. *J Clin Immunol* 2008;28(3):250-255.
22. Möller C, Xiang Z, Nilsson G. Activation of mast cells by immunoglobulin E-receptor cross-linkage, but not through adenosine receptors, induces A1 expression and promotes survival. *Clin Exp Allergy* 2003 Aug;33(8):1135-1140.
23. Ekoff M, Strasser A, Nilsson G. Fc ϵ RI aggregation promotes survival of connective tissue-like mast cells but not mucosal-like mast cells. *J Immunol* 2007 Apr;178:4177-4183.
24. Möller C, Alfredsson J, Engström M, Wootz H, Xiang Z, Lennartsson J, Jönsson J-I, Nilsson G. Stem cell factor promotes mast cell survival via inactivation of FOXO3a-mediated transcriptional induction and MEK-regulated phosphorylation of the proapoptotic protein Bim. *Blood* 2005 Aug 15;106(4):1330-1336.
25. Möller C, Karlberg M, Abrink M, Nakayama KI, Motoyama N, Nilsson G. Bcl-2 and Bcl-XL are indispensable for the late phase of mast cell development from mouse embryonic stem cells. *Exp Hematol* 2007 Mar;35(3):385-393.
26. Ullerås E, Karlberg M, Westerberg CM, Alfredsson J, Gerondakis S, Strasser A, Nilsson G. NFAT but not NF- κ B is critical for transcriptional induction of the pro-survival gene A1 after IgE receptor activation in mast cells. *Blood* 2008 Mar 15;111(6):3081-3089.

27. Liu C, Liu Z, Li Z, Wu Y. Molecular regulation of mast cell development and maturation. *Mol Biol Rep* 2010;37(4):1993-2001.
28. Roberts LJ, Oates JA. Biochemical diagnosis of systemic mast cell disorders. *J Invest Derm* 1991;96:195-255.
29. Sonneck K, Florian S, Müllauer L, Wimazal F, Födinger M, Sperr WR, Valent P. Diagnostic and subdiagnostic accumulation of mast cells in the bone marrow of patients with anaphylaxis: Monoclonal mast cell activation syndrome. *Int Arch Allergy Immunol* 2007;142:158-164.
30. Akin C, Scott LM, Kocabas CN, Kushnir-Sukhov N, Brittain E, Noel P, Metcalfe DD. Demonstration of an aberrant mast-cell population with clonal markers in a subset of patients with "idiopathic" anaphylaxis. *Blood* 2007;110:2331-2333.
31. Valent P, Akin C, Escribano L, Födinger M, Hartmann K, Brockow K, Castells M, Sperr WR, Klüin-Nelemans HC, Hamdy NA, Lortholary O, Robyn J, van Doormaals J, Sotlar K, Hauswirth AW, Arock M, Hermine O, Hellmann A, Triggiani M, Niedoszytko M, Schwartz LB, Orfao A, Horny HP, Metcalfe DD. Standards and standardization in mastocytosis: consensus statements on diagnostics, treatment recommendations and response criteria. *Eur J Clin Invest* 2007;37:435-453.
32. Molderings GJ, Kolck UW, Scheurle C, Brüß M, Homann J, Von Kügelgen I. Multiple novel alterations in Kit tyrosine kinase in patients with gastrointestinal pronounced systemic mast cell activation disorder. *Scand J Gastroenterol* 2007;42:1045-53.
33. Molderings GJ, Meis K, Kolck UW, Homann J, Frieling T. Comparative analysis of mutation of tyrosine kinase Kit in mast cells from patients with systemic mast cell activation syndrome and healthy subjects. *Immunogenetics* 2010;62:721-7.
34. Schwaab J, Schnitter S, Sotlar K, Walz C, Fabarius A, Pfirrmann M, Kohlmann A, Grossmann V, Meggendorfer M, Horny HP, Valent P, Jawhar M, Teichmann M, Metzgeroth G, Erben P, Ernst T, Hochhaus A, Haferlach T, Hofmann WK, Cross NC, Reiter A. Comprehensive mutational profiling in advanced systemic mastocytosis. *Blood* 2013; 122: 2460-2466.
35. Chan J, Tharp MD. The detection of novel KIT mutations in mastocytosis. *J Investigative Dermatol* 2013 May;133 (supp 1s): S66 (abstract 388).
36. Chan J, Kasprowicz S, Tharp MD. Distinct signalling pathways for mutated KIT(V560G) and KIT(D816V) in mastocytosis. *Clin Exp Dermatol* 2013 Jul;38(5):538-544.
37. Nedoszytko B, Nedoszytko M, Lange M, Wasag B, Zablorna M, Glen J, van Doormaals J, Varkonyi J, Aladzisy I, Rausz E, Roszkiewicz J, Zmijewski M, Nowicki R, Valent P. Genetic background of mastocytosis, a synopsis of cooperative studies conducted by ECNM. *J Investigative Dermatol* 2013 May;133 (supp 1s): S66 (abstract 391).
38. Tefferi A, Vainchenker W. Myeloproliferative neoplasms: molecular pathophysiology, essential clinical understanding, and treatment strategies. *J Clin Oncol* 2011 Feb 10;29(5):573-582.
39. Klampfl T, Harutyunyan A, Berg T, Gisslinger B, Schalling M, Bagienski K, Olcaydu D, Passamonti F, Rumi E, Pietra D, Jäger R, Pieri L, Guglielmelli P, Iacobucci I, Martinelli G, Cazzola M, Vannucchi AM, Gisslinger H, Kralovics R. Genome integrity of myeloproliferative neoplasms in chronic phase and during disease progression. *Blood* 2011 Jul 7;118(1):167-176.
40. Akin C, Valent P, Metcalfe DD. Mast cell activation syndrome: proposed diagnostic criteria. *J Allergy Clin Immunol* 2010;126:1099-1104e4.
41. Haenisch B, Nöthen MM, Molderings GJ. Systemic mast cell activation disease: the role of molecular genetic alterations in pathogenesis, heritability and diagnostics. *Immunol* 2012;137:197-205.
42. Molderings GJ, Haenisch B, Bogdanow M, Fimmers R, Nöthen MM. Familial occurrence of systemic mast cell activation disease. *PLoS One* 2013;8:e76241.
43. Valent P, Akin C, Arock M, Brockow K, Butterfield JH, Carter MC, Castells M, Escribano L, Hartmann K, Lieberman P, Nedoszytko B, Orfao A, Schwartz LB, Sotlar K, Sperr WR, Triggiani M, Valenta R, Horny H-P, Metcalfe DD. Definitions, criteria, and global classification of mast cell disorders with special reference to mast cell activation syndromes: a consensus proposal. *Int Arch Allergy Immunol* 2012;157:215-225.
44. Afrin LB, Molderings GJ. A concise, practical guide to diagnostic assessment for mast cell activation disease. *World J Hematol* 2014 Feb;3(1):1-17.
45. Molderings GJ, Brettner S, Homann J, Afrin LB. Mast cell activation disease: a concise practical guide for diagnostic workup and therapeutic options. *J Hematol Oncol* 2011;4:10, <http://www.jhoonline.org/content/4/1/10>, accessed March 28, 2014.
46. Horny HP, Metcalfe DD, Bennett JM, Bain BJ, Akin C, Escribano L, Valent P. Mastocytosis. In: Swerdlow SH, Campo E, Harris NL, et al., eds., *WHO Classification of Tumors of Hematopoietic and Lymphoid Tissues*. 4th ed. Lyon: International Agency for Research on Cancer; 2008, p. 54-63.
47. Akin C, Metcalfe DD. Chapter 15: Mastocytosis and mast cell activation syndromes presenting as anaphylaxis. In: Castells MC, ed., *Anaphylaxis and Hypersensitivity Reactions*, Springer, New York, 2011, pp. 245-256.
48. Kondo S, Kagami S, Kido H, Strutz F, Müller GA, Kuroda Y. Role of mast cell tryptase in renal interstitial fibrosis. *J Am Soc Nephrol* 2001;12:1668-1676.
49. Welker P, Krämer S, Groneberg DA, Neumayer HH, Bachmann S, Amann K, Peters H. Increased mast cell number in human hypertensive nephropathy. *Am J Physiol - Renal Physiol* 2008;295(4):F1103-F1109.
50. Barczyk M, Mysliwiec M, Kalinowski M, Rowinski M, Brzosko S. Mast cell tryptase in patients after renal transplantation. *Transplant Proc* 2008 Dec;40(10):3437-3439.
51. Guilarte M, Santos J, de Torres I, Alonso C, Vicario M, Ramos L, Martinez C, Casellas F, Saperas E, Malagelada JR. Diarrhoea-predominant IBS patients show mast cell activation and hyperplasia in the jejunum. *Gut* 2007 Feb;56(2):203-209.
52. Afrin LB. Polycythemia from mast cell activation syndrome: lessons learned. *Am J Med Sci* 2011;342:44-49.
53. Afrin LB. Mast cell activation disorder masquerading as pure red cell aplasia. *Int J Hematol* 2010;91:907-908.
54. Afrin L. Presentation, Diagnosis, and Management of Mast Cell Activation Syndrome. In: Murray D. *Mast Cells: Phenotypic Features, Biological Functions, and Role in Immunity*. Happaage, NY: Nova Science Publishers, 2013: 155-231.
55. Metcalfe DD. Mast cells and mastocytosis. *Blood* 2008 Aug 15;112(4):946-956.
56. Metcalfe DD, Baram D, Mekori YA. Mast cells. *Physiol Rev* 1997 Oct;77(4):1033-1079.
57. Yong LCJ. The mast cell: origin, morphology, distribution, and function. *Exp Toxic Pathol* 1997;49:409-424.
58. Sur R, Cavender D, Malaviya R. Different approaches to study mast cell functions. *Int Immunopharmacol* 2007 May;7(5):555-567.
59. Lim K-H, Tefferi A, Lasho TL, Finke C, Patnaik M, Butterfield JH, McClure RF, Li C-Y, Pardanani A. Systemic mastocytosis in 342 consecutive adults: survival studies and prognostic factors. *Blood* 2009;113:5727-5736.
60. Pardanani A. Systemic mastocytosis in adults: 2011 update on diagnosis, risk stratification, and management. *Am J Hematol* 2011;86:363-371.
61. Dewachter P, Castells MC, Hepner DL, Mouton-Faivre C. Perioperative management of patients with mastocytosis. *Anesthesiol* 2014 Mar;120(3):753-759.
62. Rotolo A, Familiari U, Nicoli P, Cilloni D, Saglio G, Guerrasio A. Chapter 18: Systemic mastocytosis: an intriguing disorder. In: Lawrie CH, ed., *Hematology - Science and Practice*, InTech, Rijeka, Croatia, 2012, pp. 467-486.
63. Valent P, Sperr WR, Akin C. How I treat patients with advanced systemic mastocytosis. *Blood* 2010 Dec 23;116(26):5812-5817.
64. Carter MC, Metcalfe DD, Komarow HD. Mastocytosis. *Immunol Allergy Clin N Am* 2014;34:181-196.
65. Longley J, Duffy TP, Kohn S. The mast cell and mast cell disease. *J Am Acad Dermatol* 1995 Apr;32(4):545-561.
66. Rosbotham JL, Malik NM, Syrris P, Jeffery S, Bedlow A, Garraie S, Murday VA, Holden CA, Carter ND. Lack of *c-kit* mutation in familial urticaria pigmentosa. *Br J Dermatol* 1999 May;140(5):849-852.
67. Rona RJ, Keil T, Summers C, Gislason D, Zuidmeer L, Sodergren E, Sigurdardottir ST, Lindner T, Goldhahn K, Dahlstrom J, McBride D, Madsen C. The prevalence of food allergy: a meta-analysis. *J Allergy Clin Immunol* 2007 Sep;120(3):638-646.
68. Nathan RA, Meltzer EO, Derebery J, Campbell UB, Stang PE, Corrao MA, Allen G, Stanford R. The prevalence of nasal symptoms attributed to allergies in the United States: findings from the burden of rhinitis in an America survey. *Allergy Asthma Proc* 2008 Nov-Dec;29(6):600-608.
69. Meggs WJ, Dunn KA, Bloch RM, Goodman PE, Davidoff AL. Prevalence and nature of allergy and chemical sensitivity in a general population. *Arch Environ Health* 1996 Jul-Aug;51(4):275-282.
70. Bodemer C, Hermine O, Palmérini F, Yang Y, Grandpeix-Guyodo C, Leventhal PS, Hadj-Rabia S, Nasca L, Georgin-Lavialle S, Cohen-Akenine A, Launay JM, Barete S, Feger F, Arock M, Catteau B, Sans B, Stalder JF, Skowron F, Thomas L, Lorette G, Plantin P, Bordignon P, Lortholary O, de Prost Y, Moussy A, Sobol H, Dubreuil P. Pediatric mastocytosis is a clonal disease associated with D816V and other activating c-KIT mutations. *J Invest Dermatol* 2010 Mar;130(3):804-815.